



© Mehtap Pehlivanlar Küçük,
© Burcu Öksüz Güngör,
© Ahmet Oğuzhan Küçük,
© Olcay Ayçiçek,
© Atila Türkyılmaz,
© Funda Öztuna,
© Yılmaz Bülbül,
© Tevfik Özlü

Pneumothorax and Subcutaneous Emphysema Evaluation in Patients with COVID-19 in the Intensive Care Unit

COVID-19 Tanılı Yoğun Bakım Hastalarında Pnömotoraks ve Subkütan Amfizem Olgularının Değerlendirilmesi

Received/Geliş Tarihi : 26.03.2021
Accepted/Kabul Tarihi : 19.11.2021

©Copyright 2021 by Turkish Society of Intensive Care
Turkish Journal of Intensive Care published by Galenos
Publishing House.

Mehtap Pehlivanlar Küçük
Karadeniz Technical University Faculty of Medicine,
Department of Chest Diseases, Division of Intensive
Care Medicine, Trabzon, Turkey

Burcu Öksüz Güngör, Atila Türkyılmaz
Karadeniz Technical University Faculty of Medicine,
Department of Thoracic Surgery, Trabzon, Turkey

Ahmet Oğuzhan Küçük
Karadeniz Technical University Faculty of Medicine,
Department of Anesthesiology and Reanimation,
Division of Intensive Care Medicine, Trabzon, Turkey

Olcay Ayçiçek, Funda Öztuna, Yılmaz Bülbül, Tevfik
Özlü
Karadeniz Technical University Faculty of Medicine,
Department of Chest Diseases, Trabzon, Turkey

Mehtap Pehlivanlar Küçük, PhD, (✉),
Karadeniz Technical University Faculty of Medicine,
Department of Chest Diseases, Division of Intensive
Care Medicine, Trabzon, Turkey

E-mail : mehtap_phlvnlr@hotmail.com

Phone : +90 505 242 44 90

ORCID ID : orcid.org/0000-0003-2247-4074

ABSTRACT Objective: Pneumothorax (PNX) and subcutaneous emphysema (SCE) have increased in importance as a frequently occurring complication. This study aimed to reveal the frequency, timing, and possible risk factors in patients with PNX and SCE who are followed up with coronavirus disease-2019 (COVID-19) diagnosis in our tertiary intensive care unit (ICU).

Materials and Methods: All patients with confirmed COVID-19 who were followed up and treated in our unit between August 8, 2020, and February 20, 2021, in a 16-bed tertiary ICU and who developed PNX and SCE during their hospitalization were included.

Results: PNX and SCE developed in 16 (9.6%) of 165 patients who were followed up in our ICU due to COVID-19. Of these 16 patients, 3 (18.8%) survived. The median age of patients was 66.5 years (interquartile range: 58.5-75.5). Diabetes mellitus was the most common comorbidity in patients with PNX and SCE. Additionally, 12 (75%) patients had a smoking history. Of 15 (93.8%) patients who developed PNX, 4 (25%) were bilateral, and SCE developed in 9 (56.3%) patients. Twelve (75%) patients with PNX and SCE were under invasive mechanical ventilation, 3 (18.8%) under spontaneous breathing, and 1 (6.2%) under non-invasive mechanical ventilation treatment. The number of oxygen support days until the time PNX and SCE developed was 9 (6.25-17) days in the whole group, the median time was 6 days in the survival group and 9 days in the non-survival group.

Conclusion: In the COVID-19 pandemic, complications, such as PNX and SCE, are more frequently observed (9.5%) than in the general intensive care population and the later period of intensive care admission (median 9 days). Smoking is defined as a risk factor in most of these patients; however, increased PNX rates are thought to be related to both COVID-19 pneumonia and parenchymal damage due to cytokine storms.

Keywords: COVID-19, pneumothorax, intensive care unit

ÖZ Amaç: Koronavirüs hastalığı-2019 (COVID-19) ile takipli yoğun bakım hastalarında pnömotoraks (PNX)/deri altı amfizem (SCE) pandeminin ilk zamanlarında yapılan tanımlamaların aksine sık ortaya çıkan bir komplikasyon olarak önemini artırmaktadır. Bu çalışma ile 3. düzey yoğun bakım ünitemizde (YBÜ) COVID-19 tanısı ile takip edilen PNX/SCE olgularının sıklığını, zamanlamasını ve olası risk faktörlerini ortaya koymak hedeflenmiştir.

Gereç ve Yöntem: On altı yataklı 3. düzey YBÜ'de, 28 Ağustos 2020 ve 20 Şubat 2021 arasında ünitemizde takip ve tedavi edilmiş tüm teyitli COVID-19 hastalarından, yatışları sırasında PNX ve SCE gelişen olgular dahil edilmiştir.

Bulgular: Hedef tarih aralığında YBÜ'de COVID-19 nedeni ile 165 hasta takip edilmiş olup bu hastaların 16'sında (%9,6) PNX/SCE gelişmiştir. Bu 16 hastanın 4'ü (%25) sağ kalmıştır. Hastaların medyan yaşı 66,5 (çeyrekler açıklığı: 58,5-75,5) idi. PNX/SCE gelişen hastalarda en sık komorbiditye diabetes mellitus olarak tespit edildi. Hastaların 12'sinin (%75) sigara kullanım öyküsü mevcuttu. PNX gelişen 15 (%93,8) hastanın 4'ü (%25) bilateral idi. SCE ise 9 (%56,3) hastada gelişti. PNX/SCE saptanan 12 (%75) hasta invazif mekanik ventilasyon tedavisi altındayken, 3 (%18,8) hasta spontan solunumda, 1 (%6,2) hasta non-invazif mekanik ventilasyon tedavisi altındaydı. PNX/SCE geliştiği ana kadar oksijen desteği verilen gün sayısı tüm grupta 9 (6,25-17) gün iken, sağkalan grupta medyan değer 6 gün, ölen grupta 9 gün idi. Oksijen destek gün süresi ölen grupta yüksek olsa da istatistiksel anlamlı fark saptanmadı (p=0,439).

Sonuç: COVID-19 pandemisinde PNX/SCE gibi komplikasyonlar uzun süreli oksijen desteğini takiben genel yoğun bakım popülasyonundan daha sık (%9,5) ve yoğun bakım yatışının daha geç döneminde (medyan 9 gün) gözlenmektedir. Bu hastaların çoğunda bir risk faktörü olarak sigara tanımlansa da PNX oranlarındaki bu artışın hem COVID-19 pnömonisi hem de sitokin fırtınasına bağlı oluşan parankimal hasar ile ilgili olduğunu düşünüyoruz.

Anahtar Kelimeler: COVID-19, pnömotoraks, yoğun bakım ünitesi

Introduction

The nature of the severe acute respiratory syndrome coronavirus 2 (SARS-CoV-2) virus, which entered our lives as a pandemic agent, is still not clearly known. The virus, which can cause complex and fatal complications, involves many organ systems and often requires intensive care support. Respiratory failure in patients is usually characterized by air bronchograms, bilateral interstitial infiltrates, and multiple lobar and subsegmental consolidations which are seen as ground glass opacities on computed tomography (CT) (1). Coronavirus disease-2019 (COVID-19) has many diagnosed complications such as arrhythmia, cardiogenic shock, renal and hepatic involvement, thromboembolism, and acute respiratory distress syndrome (ARDS) (2-4). Pneumothorax (PNX) and pneumomediastinum are common complications of mechanical ventilation (5,6). While there is a noticeable increase in the frequency of these complications in COVID-19 patients, spontaneous PNX/pneumomediastinum cases have also been described without barotrauma (7). One large review reported 18 different COVID-19-related spontaneous PNX cases followed in different centers (8). In our study, we aimed to reveal the frequency, timing, and possible risk factors of PNX and subcutaneous emphysema (SCE) cases followed up with the diagnosis of COVID-19 in our tertiary intensive care unit.

Materials and Methods

Our study was carried out in Karadeniz Technical University Faculty of Medicine 16-bed tertiary intensive care unit with the approval of the local Ethics Committee of Karadeniz Technical University Faculty of Medicine (protocol no: 2021/62, date: 25.03.2021) and the Ministry of Health. All cases were diagnosed according to the typical radiological image on CT or Real time polymerase chain reaction diagnosis of SARS-CoV-2 infection. All confirmed COVID-19 patients who were followed up and treated in our unit between August 28, 2020 and February 20, 2021 and who developed PNX and SCE during their hospitalization were included in the study.

The diagnoses of the patients were made by bedside ultrasonography (USG) and direct anteroposterior chest radiographs taken in the bed.

Patient data were obtained from retrospective intensive care patient registry, data processing automation records, and clinical course. Radiological images of the patients

were accessed from the hospital picture archiving and communication system.

In our study, demographic data of the cases, comorbidities, possible risk factors for PNX, clinical, radiological, and laboratory data, applied oxygen support system [high-flow nasal cannula (HFNC), invasive mechanical ventilation (IMV), non-invasive mechanical ventilation (NIMV)], whether prone position was applied, other medical treatments applied for primary disease, and patient outcome information was recorded. HFNC was administered at a flow rate of 60 l/min in each patient during the initial phase. In the follow-up, the flow rate was decreased according to respiratory effort of the patients. Surgical procedure (chest tube insertion, etc.) applied to the patient due to PNX/SCE was recorded.

Statistical Analysis

Data were analyzed with IBM SPSS V23 (Chicago, USA). The compliance of the data to normal distribution was examined using the Shapiro-Wilk test. Non-normally distributed data are presented as the median [interquartile range (IQR): 25-75]. Categorical data are presented as frequency and percentage. The study population was divided in to two groups according to outcome (survived and non-survived). Kruskal-Wallis test and Mann-Whitney U test were used to compare quantitative data that did not show normal distribution. Chi-square test was used to compare qualitative data. The significance level was taken as $p < 0.05$.

Results

One hundred sixty-five patients were followed in our intensive care unit due to COVID-19, and 16 (9.6%) of these patients developed PNX/SCE (Figure 1).

Three (18.8%) of these 16 patients survived. Analyses were made by grouping the patients according to the mortality outcome. The median age of the patients was 66.5 years (IQR: 58.5-75.5), and 12 of the patients were male and 4 were female. While all of the female patients died, no mortality was observed in 25% of the male patients. Diabetes mellitus was the most common comorbidity in patients with PNX/SCE, and there was no significant difference in mortality in any of the comorbidities.

Four (25%) of the 15 (93.8%) patients who developed PNX were bilateral. SCE developed in 9 (56.3%) patients. While chest tube drainage system was set up in 11 (68.8%) patients, 5 (31.2%) patients were followed conservatively without surgical intervention. PNX/SCE was detected in one

of the cases in the regression period of covid pneumonia and in the others in ARDS.

HFNC was the most commonly used respiratory support treatment method and was applied to 13 (81.3%) patients. Twelve patients (75%) were placed in the prone position. While all 16 patients were receiving low dose methylprednisolone treatment, 5 (31.2%) patients received pulse methylprednisolone, 11 (68.8%) patients tocilizumab, 2 (12.5%) patients tocilizumab and pulse methylprednisolone together, and 9 (56.3%) patients received immune plasma treatment. There was no significant difference in mortality in patients who developed PNx/SCE according to these treatments.

Twelve (75%) patients with PNx/SCE were under IMV treatment, three (18.8%) patients were under spontaneous breathing, and one patient (6.2%) was under NIMV treatment (Table 1). The most dominant risk factor in all patients was smoking. While 12 (75%) of the patients had a smoking history, there was no significant difference in mortality between smoking and non-smoking groups ($p=0.607$). When the chest tomography at admission was evaluated, there was no dominant risk factor for PNx/SCE, while three patients had traction bronchiectasis.

The duration of smoking was 30 packs/year (IQR: 25-38.75) in all patients. While the number of days given oxygen support until the time PNx/SCE developed was 9 (6.25-17) days in the whole group, the median value was 6 days in the survival group and 9 days in the non-survival group. Although the time spent on oxygen support was higher in the non-

survival group, no significant difference was found ($p=0.439$). There was no significant difference in terms of IMV duration ($p=0.439$). The duration of stay in the intensive care unit and the duration of hospital stay were significantly shorter in the non-survival group ($p=0.005$, $p=0.014$ respectively) (Table 2).

Discussion

Since the beginning of the COVID-19 pandemic, clinicians' experience with the disease and its complications has increased. Intensive care units have become units where COVID-19 patients under severe respiratory distress are closely monitored. PNx/SCE has increased in importance as a frequent complication in intensive care patients, contrary to the definitions made in the early stages of the pandemic. In a study, 94 of 3,430 intensive care patients had iatrogenic PNx; 42 of them were associated with barotrauma, while 52 were associated with the invasive procedure. The cumulative incidence was determined to be 1.4% (9). Although PNx/SCE is observed at a very low rate in general intensive care, it was seen at a much higher rate (20-34%) in intubated patients in the SARS outbreak caused by a coronavirus strain (10,11). Although PNx/SCE was defined in 16 (9.6%) of 165 intensive care patients in intensive care unit, this frequency was given as 1-2% in two separate studies conducted in the early stages of the pandemic in China (12,13). In addition, more recent case reports are available in the literature (7,8,14-17).

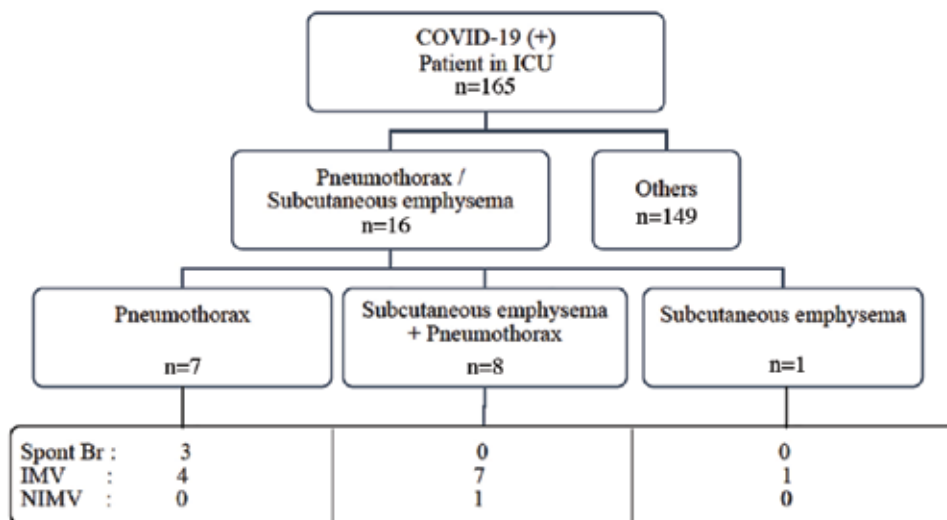


Figure 1. COVID-19 patient diagram

COVID-19: Coronavirus disease-2019, IMV: invasive mechanical ventilation, NIMV: non-invasive mechanical ventilation, ICU: intensive care unit

Even if PNx is suspected in intensive care units, confirmation of the diagnosis is much more difficult than in clinic patients whose condition is stable. PNx cases, which are mostly diagnosed by direct radiographs taken at the bedside, are also diagnosed by bedside USG in our unit (Figure 2). Lung sliding loss occurs in lung USG and stratosphere sign occurs in M mode in PNx. Lung sliding and/or B lines exclude the diagnosis of PNx (18,19). Lung USG was performed in all of the presented cases, and the diagnosis was confirmed by direct radiographs at the bedside.

PNx/SCE cases associated with barotrauma, which are among the complications of mechanical ventilation

in intensive care units, can be considered as common complications. Therefore, lung protective mechanical ventilation strategies should be adopted. In the recently published Surviving Sepsis Campaign update, it is suggested as "For mechanically ventilated adults with COVID-19 and ARDS, targeting Pplat of <30 cm H₂O, they suggest using a higher positive end-expiratory pressure (PEEP) strategy over a lower PEEP strategy in moderate to severe ARDS, If using a higher PEEP strategy (i.e., PEEP >10 cm H₂O), clinicians should monitor patients for barotrauma." (20). There are also studies where mechanical ventilation does not increase the risk of barotrauma when lung protective mechanical ventilation rules apply (21,22).

Table 1. Demographic characteristics of the patients

			Total	Survived	Did not survive
			n	n (%)	n (%)
Risk factors	Smoking	No	4	1 (25)	3 (75)
		Yes	12	2 (16.7)	10 (83.3)
	Chronic lung disease	No	13	3 (23.1)	10 (76.9)
		Yes	3	0 (0)	3 (100)
	Cough attack	No	16	3 (18.8)	13 (81.3)
		Yes	0	0 (0)	0 (0)
Admission CT findings	Air cyst	No	14	3 (21.4)	11 (78.6)
		Yes	2	0 (0)	2 (100)
	Bullae	No	15	3 (20)	12 (80)
		Yes	1	0 (0)	1 (100)
	Traction bronchiectasis	No	13	2 (15.4)	11 (84.6)
		Yes	3	1 (33.3)	2 (66.7)
Respiratory support on PNx	Spontaneous breathing	No	13	1 (7.7)	12 (92.3)
		Yes	3	2 (66.7)	1 (33.3)
	IMV	No	4	2 (50)	2 (50)
		Yes	12	1 (8.3)	11 (91.7)
	NIMV	No	15	3 (20)	12 (80)
		Yes	1	0 (0)	1 (100)

IMV: Invasive mechanical ventilation, NIMV: non-invasive mechanical ventilation, PNx: pneumothorax, CT: computed tomography

Table 2. Comparison of outcomes in survived and non-survived groups

	Total	Survived (n=13)	Non-survived (n=3)	P
Duration of smoking, (packs/year)	30 (25-38.75)	30 (25-36.25)	35 (25-)	0.758
Number of days given oxygen support until the time PNx/SCE developed	9 (6.25-17)	9 (7-17)	6 (1-)	0.439
Duration of IMV, (days)	11 (4.5-18.5)	10 (5-16.5)	19 (0-)	0.611
Duration of ICU stay, (days)	18 (11.75-24.75)	16 (10.5-21)	25 (24-)	0.005
Duration of hospital stay, (days)	21 (17.5-27)	19 (14-22.5)	31 (27-)	0.014

PNx: Pneumothorax, SCE: subcutaneous emphysema, IMV: invasive mechanical ventilation, ICU: intensive care unit

However, it is interesting to detect cases of PNx/SCE in COVID-19 pneumonia not only in the case of high-pressure ventilation but also in spontaneously breathing patients. Moreover, no risk factor was found in many of the reported cases (7,8). In three of our patients, PNx developed during spontaneous breathing under oxygen therapy with HFNC. Two of these patients were under the age of 45, without additional risk factors for PNx. One of the two patients developed PNx, which required chest tube drainage while spontaneously breathing on the 19th and the other on the 24th day of oxygen therapy; one of these patients died. In the general intensive care population, barotrauma is seen earlier, and the median time is reported to be 4-5 days after intubation (9).

In our patients, PNx/SCE complications generally developed in the later stages of the disease, on average

at 9 (6-17) days of oxygen therapy. Moreover, there were facilitating factors such as air cyst, bullae, and traction bronchiectasis in 6 patients' thoracic CT at the time of admission to the hospital. This timing corresponds to days 11-28, which is defined as the early pulmonary phase/late pulmonary phase of the COVID pneumonic process and its intense oxygen demand (23). In general, known risk factors for the development of primary spontaneous PNx include age between 10 and 30 years, male gender, tall height, and weak body structure. Secondary causes include smoking, chronic obstructive pulmonary disease, infections, alpha-1 antitrypsin deficiency, and trauma (24,25). Not surprisingly, 75% of our patients were smokers, and most of them (83.3%) died.

In the COVID-19 pandemic, oxygen support systems have unfortunately had to be used in increasing doses and

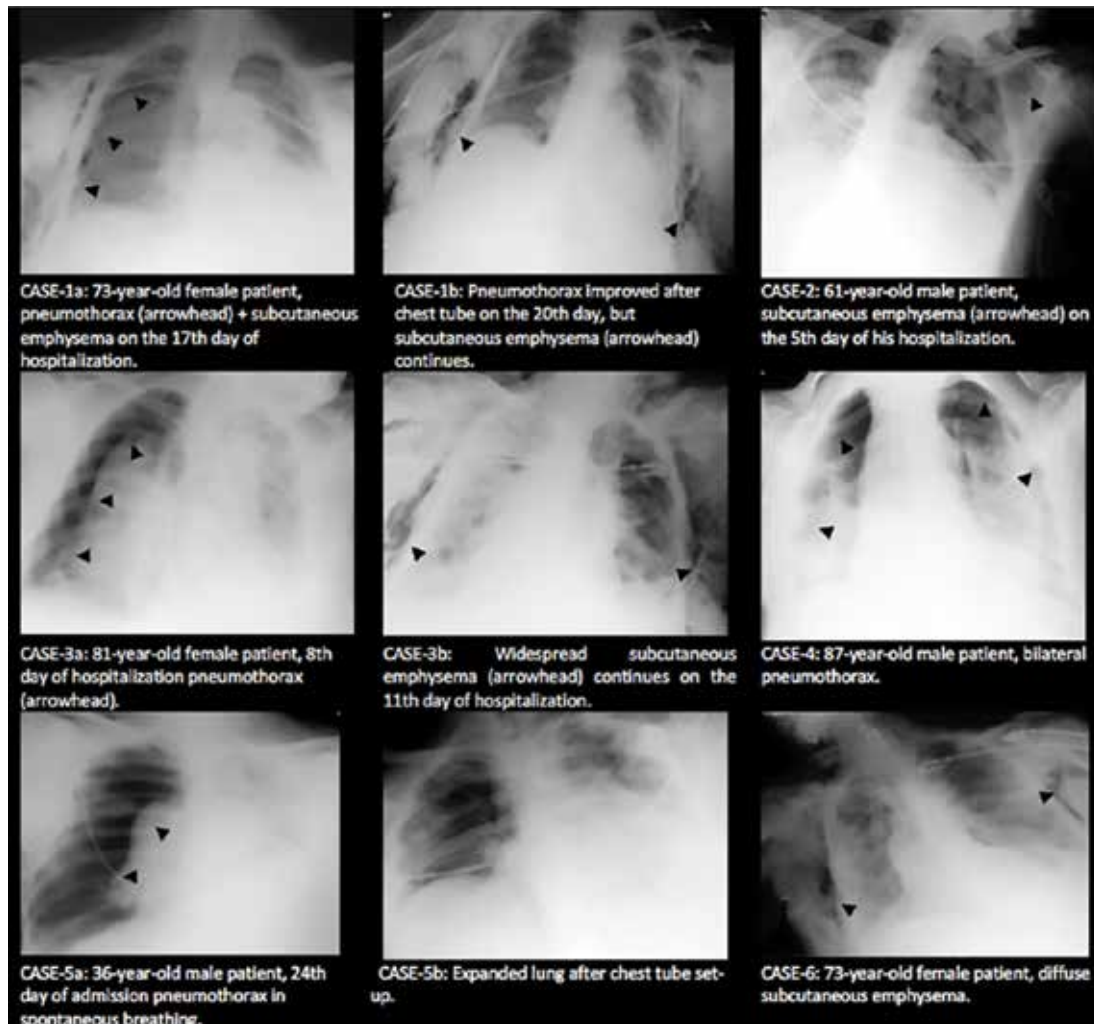


Figure 2. Examples of bedside radiography

for a long time. When focusing on acute respiratory failure treatment in COVID-19 patients, the long-term effects of intense oxygen exposure can be ignored. Many healthy volunteers experience pleuritic chest pain, cough, substernal heaviness, and shortness of breath within a day of inhaling 100% oxygen; these symptoms are commonly due to a combination of absorptive atelectasis and tracheobronchitis (26). Most patients treated with a high FiO_2 (> 90%) more than six hours may have edema and bronchoscopic erythema in the large airways, which is thought to reflect hyperoxic bronchitis (27). In addition, regardless of the presence of underlying lung disease the reactive oxygen intermediate concentration in the exhaled gas increases only one hour after inhaling 28% oxygen (28). Free oxygen radicals also stimulate the harmful inflammatory response caused to secondary tissue damage and/or apoptosis (29). Some of the hypotheses already put forward for the development of PNX/SCE in COVID-19 pneumonia can be listed as follows: occlusion of small airways due to inflammation rises alveolar pressure and causes ruptures with air leaks into the lung interstitium; air travels to the hilum through the bronchovascular sheaths and collects in the mediastinum causing pneumomediastinum; the rupture of the mediastinal parietal pleura causes PNX. In addition, inflammatory cells associated with interleukin-6, which are produced during the cytokine storm associated with SARS-CoV-2, cause bullae formation in the lung by destroying elastic fibers (30,31). On the other hand, edema, vascular occlusion, and microthrombi may contribute to the rupture of pre-existing bullae (26). In our patients, PNX/SCE generally developed in the later stages of the disease and on the ninth day of oxygen therapy, while six patients had facilitating factors such as air cyst, bulla, and traction bronchiectasis on thoracic CT at the admission to the hospital.

PNX should be suspected in patients even if there are no risk factors such as invasive or non-invasive positive pressure ventilator support, smoking and chronic lung disease, or severe cough. While mild cases can spontaneously resolve with close monitoring, oxygen support, and analgesia, patients with severe respiratory failure, such as our patients, may develop alveolar damage and alveolar rupture more easily and often require chest tube drainage. In these patients, chest tube drainage should be continued until the patients are extubated if they are intubated, and in

patients with spontaneous breathing, when the lung is fully expanded and should be continued until 24 hours after the leak has ceased. The limitations of study were; CORADS classification was not used in radiological evaluation and total number of cases is low hence power of study wasn't reached wanted value.

Conclusion

In intensive care patients who are followed up due to COVID-19 and require high fractionated oxygen, in the case of acute or worsening dyspnea, PNX/SCE should be suspected in these patients with or without mechanical ventilation support. In the COVID-19 pandemic, these complications can be observed more frequently (9.5%) than in the general intensive care population and in the later period of intensive care admission (median 9 days). Although smoking is defined as a risk factor in most of these patients, we think that the increase in PNX rates is not only associated with the presence of a certain risk factor or barotrauma, but primarily related to both COVID-19 pneumonia and parenchymal damage caused by cytokine storm. These patients should be closely monitored for these complications in their long-term follow-up.

Ethics

Ethics Committee Approval: The approval of the local Ethics Committee of Karadeniz Technical University Faculty of Medicine (protocol no: 2021/62, date: 25.03.2021) and the Ministry of Health.

Informed Consent: Retrospective study.

Peer-review: Externally and internally peer-reviewed.

Authorship Contributions

Surgical and Medical Practices: M.P.K., O.A., A.T., F.Ö., Y.B., T.Ö., Concept: M.P.K., B.Ö.G., A.O.K., O.A., A.T., F.Ö., Y.B., T.Ö., Design: M.P.K., A.O.K., O.A., A.T., F.Ö., Y.B., T.Ö., Data Collection or Processing: M.P.K., B.Ö.G., A.O.K., Analysis or Interpretation: M.P.K., A.O.K., O.A., Literature Search: M.P.K., B.Ö.G., Writing: M.P.K., A.O.K., B.Ö.G., O.A., A.T., F.Ö., Y.B., T.Ö.

Conflict of Interest: No conflict of interest was declared by the authors.

Financial Disclosure: The authors declared that this study received no financial support.

References

- Salehi S, Abedi A, Balakrishnan S, Gholamrezanezhad A. Coronavirus Disease 2019 (COVID-19): A Systematic Review of Imaging Findings in 919 Patients. *AJR Am J Roentgenol* 2020;215:87-93.
- Wang D, Hu B, Hu C, Zhu F, Liu X, Zhang J, et al. Clinical Characteristics of 138 Hospitalized Patients With 2019 Novel Coronavirus-Infected Pneumonia in Wuhan, China. *JAMA* 2020;323:1061-9.
- Klok FA, Kruip MJHA, van der Meer NJM, Arbous MS, Gommers DAMPJ, Kant KM, et al. Incidence of thrombotic complications in critically ill ICU patients with COVID-19. *Thromb Res* 2020;191:145-7.
- Yang F, Shi S, Zhu J, Shi J, Dai K, Chen X. Analysis of 92 deceased patients with COVID-19. *J Med Virol* 2020;92:2511-5.
- Yao W, Wang T, Jiang B, Gao F, Wang L, Zheng H, et al. Emergency tracheal intubation in 202 patients with COVID-19 in Wuhan, China: lessons learnt and international expert recommendations. *Br J Anaesth* 2020;125:e28-e37.
- Jacobi A, Chung M, Bernheim A, Eber C. Portable chest X-ray in coronavirus disease-19 (COVID-19): A pictorial review. Vol. 64, *Clinical Imaging*. Elsevier Inc; 2020. p. 35-42.
- Elhakim TS, Abdul HS, Pelaez Romero C, Rodriguez-Fuentes Y. Spontaneous pneumomediastinum, pneumothorax and subcutaneous emphysema in COVID-19 pneumonia: a rare case and literature review. *BMJ Case Rep* 2020;13:e239489.
- Alhakeem A, Khan MM, Al Soub H, Yousaf Z. Case Report: COVID-19-Associated Bilateral Spontaneous Pneumothorax-A Literature Review. *Am J Trop Med Hyg* 2020;103:1162-5.
- de Lasseance A, Timsit JF, Tafflet M, Azoulay E, Jamali S, Vincent F, et al. Pneumothorax in the intensive care unit: incidence, risk factors, and outcome. *Anesthesiology* 2006;104:5-13.
- Lew TW, Kwek TK, Tai D, Earnest A, Loo S, Singh K, et al. Acute respiratory distress syndrome in critically ill patients with severe acute respiratory syndrome. *JAMA* 2003;290:374-80.
- Fowler RA, Lapinsky SE, Hallett D, Detsky AS, Sibbald WJ, Slutsky AS, et al. Critically ill patients with severe acute respiratory syndrome. *JAMA* 2003;290:367-73.
- Chen N, Zhou M, Dong X, Qu J, Gong F, Han Y, et al. Epidemiological and clinical characteristics of 99 cases of 2019 novel coronavirus pneumonia in Wuhan, China: a descriptive study. *Lancet* 2020;395:507-13.
- Yang X, Yu Y, Xu J, Shu H, Xia J, Liu H, et al. Clinical course and outcomes of critically ill patients with SARS-CoV-2 pneumonia in Wuhan, China: a single-centered, retrospective, observational study. *Lancet Respir Med* 2020;8:475-81.
- George B, Megally M, Mrejen-Shakin K. Spontaneous pneumothorax and spontaneous pneumomediastinum in non-intubated patients in the setting of Severe Acute Respiratory Syndrome Coronavirus 2. *Chest* 2020;158:A1653-4.
- Muhammad AI, Boynton EJ, Naureen S. COVID-19 with bilateral pneumothoraces- case report. *Respir Med Case Rep* 2020;31:101254.
- Talan L, Şaşal Solmaz FG, Ercan U, Akdemir Kalkan İ, Yenigün BM, Yüksel C, et al. COVID-19 pneumonia and pneumothorax: case series. *Tuberk Toraks* 2020;68:437-43.
- Vahapoğlu A, Akpolat B, Çavuş Z, Genç Moralar D, Türkmen A. Spontaneous Hemopneumothorax During the Course of COVID-19 Pneumonia. *Turkish J Intensive Care* 2020;18:46-9.
- Lichtenstein D, Mezière G, Biderman P, Gepner A. The "lung point": an ultrasound sign specific to pneumothorax. *Intensive Care Med* 2000;26:1434-40.
- Lichtenstein DA, Lascols N, Prin S, Mezière G. The "lung pulse": an early ultrasound sign of complete atelectasis. *Intensive Care Med* 2003;29:2187-92.
- Alhazzani W, Möller MH, Arabi YM, Loeb M, Gong MN, Fan E, et al. Surviving Sepsis Campaign: guidelines on the management of critically ill adults with Coronavirus Disease 2019 (COVID-19). *Intensive Care Med* 2020;46:854-87.
- Özdemir S, Bilgi DÖ, Köse S, Oya G. Pneumothorax in patients with coronavirus disease 2019 pneumonia with invasive mechanical ventilation. *Interact Cardiovasc Thorac Surg* 2021;32:351-5.
- Güven BB, Ertürk T, Kompe Ö, Ersoy A. Serious complications in COVID-19 ARDS cases: pneumothorax, pneumomediastinum, subcutaneous emphysema and haemothorax. *Epidemiol Infect* 2021;149:e137.
- EVMS COVID-19 Management protocol An overview of the MATH+ and I-MASK+ Protocols. 2020.
- Gupta D, Hansell A, Nichols T, Duong T, Ayres JG, Strachan D. Epidemiology of pneumothorax in England. *Thorax* 2000;55:666-71.
- Sahn SA, Heffner JE. Spontaneous pneumothorax. *N Engl J Med* 2000;342:868-74.
- Comroe JH, Dripps RD, Dumke PR, Deming M. Oxygen toxicity: The effect of inhalation of high concentrations of oxygen for twenty-four hours on normal men at sea level and at a simulated altitude of 18,000 feet. *J Am Med Assoc* 1945;128:710-7.
- Sackner MA, Landa J, Hirsch J, Zapata A. Pulmonary effects of oxygen breathing. A 6-hour study in normal men. *Ann Intern Med* 1975;82:40-3.
- Carpagnano GE, Kharitonov SA, Foschino-Barbaro MP, Resta O, Gramiccioni E, Barnes PJ. Supplementary oxygen in healthy subjects and those with COPD increases oxidative stress and airway inflammation. *Thorax* 2004;59:1016-9.
- Mantell LL, Lee PJ. Signal transduction pathways in hyperoxia-induced lung cell death. *Mol Genet Metab* 2000;71:359-70.
- Zhang C, Wu Z, Li JW, Zhao H, Wang GQ. Cytokine release syndrome in severe COVID-19: interleukin-6 receptor antagonist tocilizumab may be the key to reduce mortality. *Int J Antimicrob Agents* 2020;55:105954.
- Marini JJ, Gattinoni L. Management of COVID-19 Respiratory Distress. *JAMA* 2020;323:2329-30.