



© Reyhan Akkurt,  
© Ebru Karakoç,  
© Birgül Yelken

## HSV and SARS-CoV-2 Encephalitis “Or to Take Arms Against a Sea of Troubles (W. Shakespeare)”

### HSV ve SARS-CoV-2 Ensefaliti “Veya Bir Deniz Dolusu Sıkıntıya Karşı Silahları Kuşanmak (W. Shakespeare)”

Received/Geliş Tarihi : 18.09.2023  
Accepted/Kabul Tarihi : 24.10.2023

©Copyright 2023 by the Turkish Society of Intensive Care / Turkish Journal of Intensive Care is published by Galenos Publishing House.

Licensed under a Creative Commons Attribution-NonCommercial-NoDerivatives 4.0 (CC BY-NC-ND) International License.

Reyhan Akkurt  
Eskişehir Osmangazi University Faculty of Medicine,  
Department of Anesthesiology and Reanimation,  
Eskişehir, Turkey

Ebru Karakoç, Birgül Yelken  
Eskişehir Osmangazi University Faculty of Medicine,  
Department of Anesthesiology and Reanimation,  
Division of Intensive Care, Eskişehir, Turkey

Reyhan Akkurt (✉),  
Eskişehir Osmangazi University Faculty of Medicine,  
Department of Anesthesiology and Reanimation,  
Eskişehir, Turkey

E-mail : reyhan\_akkurt@hotmail.com

Phone : +90 545 903 25 93

ORCID ID : orcid.org/0009-0008-9055-1493

**Presented in:** This case presentation has been published as a paper at the 24<sup>th</sup> International Intensive Care Symposium.

**ABSTRACT** Published data suggest that encephalitis is one of the most fatal neurologic manifestations of coronavirus disease-2019 (COVID-19) involving both adult and pediatric patients. Herpes simplex virus (HSV) encephalitis is one of the most common causes of sporadic encephalitis. There have been cases of systemic and pulmonary reactivation of HSV due to immune dysregulation following COVID-19 infection. An 88-year-old woman diagnosed with Alzheimers disease was admitted to the intensive care unit (ICU) with fever and general condition disorder. On admission, the patient with fever and neck stiffness was found to be positive for HSV DNA in the cerebrospinal fluid (CSF) sample studied with lumbar puncture (LP) and positive for COVID polymerase chain reaction (PCR) in the nasopharyngeal swab sample taken together. While the COVID PCR test was positive in the CSF sample studied with LP performed on the 9<sup>th</sup> day of intensive care hospitalization, HSV DNA was found to be negative in the patient whose acyclovir treatment was continued. The COVID PCR test was also positive in the nasopharyngeal swab sample taken at the same time. Cardiac arrest occurred after sudden desaturation, and the patient was resuscitated for 6 min on the 11<sup>th</sup> day of ICU admission. Left frontotemporal epileptic activity in bedside electroencephalography was evaluated in favor of focal disorganization. In addition to frontotemporal lobe involvement, which is common in HSV and COVID-19 encephalitis, we want to report the coexistence of these two viruses. We believe that this case report should help professionals remind co-infections of HSV and severe acute respiratory syndrome coronavirus-2 to cure the morbidity appropriately.

**Keywords:** HSV encephalitis, COVID-19, CSF PCR, COVID-19 encephalitis

**ÖZ** Yayınlanan veriler, ensefalitin, hem yetişkin hem de pediatrik hastaları kapsayan, koronavirüs hastalığı-2019'un (COVID-19) en ölümcül nörolojik belirtilerinden biri olduğunu öne sürmektedir. Herpes simpleks virüs (HSV) ensefaliti, sporadik ensefalitin en yaygın nedenlerinden biridir. COVID-19 enfeksiyonunu takiben immün düzensizlik nedeniyle HSV'nin sistemik ve pulmoner reaktivasyonunu bildiren olgular olmuştur. Alzheimer tanısı alan 88 yaşındaki kadın, ateş ve genel durum bozukluğu şikayetiyle yoğun bakım ünitesine (YBÜ) kabul edildi. Başvuru sırasında ateşi ve ense sertliği olan hastanın lomber ponksiyon ile çalışılan beyin omurilik sıvı (BOS) örneğinde HSV DNA pozitifliği, birlikte alınan nazofaringeal sürüntü örneğinde ise COVID polimeraz zincirleme reaksiyonu (PZR) pozitifliği belirlendi. Yoğun bakıma yatışının 9. gününde yapılan lomber ponksiyon (LP) ile çalışılan BOS örneğinde COVID PZR testi pozitif çıkarken, asiklovir tedavisine devam edilen hastanın HSV DNA'sı negatif olduğu belirlendi. Aynı anda alınan nazofaringeal sürüntü örneğinde de COVID PZR testi pozitif çıktı. YBÜ'ye yatışının 11. gününde ani desatürasyon sonrası kardiyak arrest gelişen ve 6 dakika süreyle kardiyopulmoner resüsitasyon uygulanan hasta resüsitasyona yanıt verdi. Yatak başı elektroensefalografide sol frontotemporal epileptik aktivite ve fokal dezorganizasyon lehine değerlendirildi. HSV ve COVID-19 ensefalitinde frontotemporal lob tutulumunun yaygın olmasının yanı sıra bu iki virüsün bir arada varlığını da bildirmek istiyoruz. Bu olgu raporunun, profesyonellerin HSV ve şiddetli akut solunum sendromu koronavirüs-2'nin birlikte enfeksiyonlarını, morbiditeyi uygun şekilde tedavi etmek için hatırlatmalarına yardımcı olacağını düşünüyoruz.

**Anahtar Kelimeler:** HSV ensefaliti, COVID-19, BOS PZR, COVID-19 ensefaliti

## Introduction

Severe acute respiratory syndrome coronavirus-2 (SARS-CoV-2), which emerged in Wuhan, China in December 2019, infected 767,518,723 people and killed 6.947.192 (1). Although most coronavirus disease-2019 (COVID-19) patients present with fever, cough, respiratory distress-shortness of breath, many published studies have demonstrated the neuroinvasive potential and neurological involvement of the virus. While discussions on the mechanism of central nervous system invasion continue, two hypotheses have been focused on; direct viral invasion; indirect damage by inflammatory and autoimmune pathways (2,3). It has also been argued that the neuroinvasive potential of SARS-CoV-2 may be one of the causes of respiratory failure (4).

The first case of encephalitis secondary to SARS-CoV-2 is a patient with aseptic encephalitis who was admitted to China in February 2020 with symptoms of headache, fatigue, and fever, and SARS-CoV-2 RNA was detected in the cerebrospinal fluid (CSF) of the study (5).

In this case report, we aimed to present a patient with herpes simplex virus (HSV) encephalitis and a positive COVID polymerase chain reaction (PCR) taken from a nasopharyngeal sample, and a patient with a positive COVID PCR in the CSF studied in the intensive care unit (ICU).

## Case Report

An 88-year-old female patient with no known chronic disease other than Alzheimer's, who could be mobile with home support, had a history of general condition disorder and decreased oral intake that started approximately one week before her admission to the hospital. Two days before admission to the hospital, fever and wheezing were added to the patient's symptoms.

On admission to the emergency department, her Glasgow coma scale (GCS) was E4M5V3. Her fever was 38 degrees, tachypneic, and O<sub>2</sub>-free peripheral oxygen saturation was 86-90. When her conscious state was evaluated, she was disorientated and uncooperative. On physical examination, lung sounds were deep and coarse, but no pathological sound was heard. In the neurological examination, nuchal rigidity, kerning and brudzinski were positive; the light reflex of the patient was taken and no lateralizing signs were detected. Electrocardiogram was in atrial fibrillation rhythm.

No signs of intracerebral hemorrhage or an appearance compatible with the mass were observed in the brain computed tomography (CT). Appearances consistent with chronic ischemia were detected in the periventricular white matter and diffusion magnetic resonance imaging (MRI) did not detect pathological diffusion restriction. On the thorax CT examination, sequela parenchymal changes and mosaic pattern were observed in both lungs.

A lumbar puncture was performed in the patient who did not have acute pathology in the brain CT. No microorganism was observed in the direct microscopic examination without dye and gram staining studied from the CSF sample, and pathogenic bacteria didn't grow in the CSF culture. In the meningitis/encephalitis panel studied, HSV-1 was positive. The patient was given 600 mg acyclovir treatment considering infectious diseases.

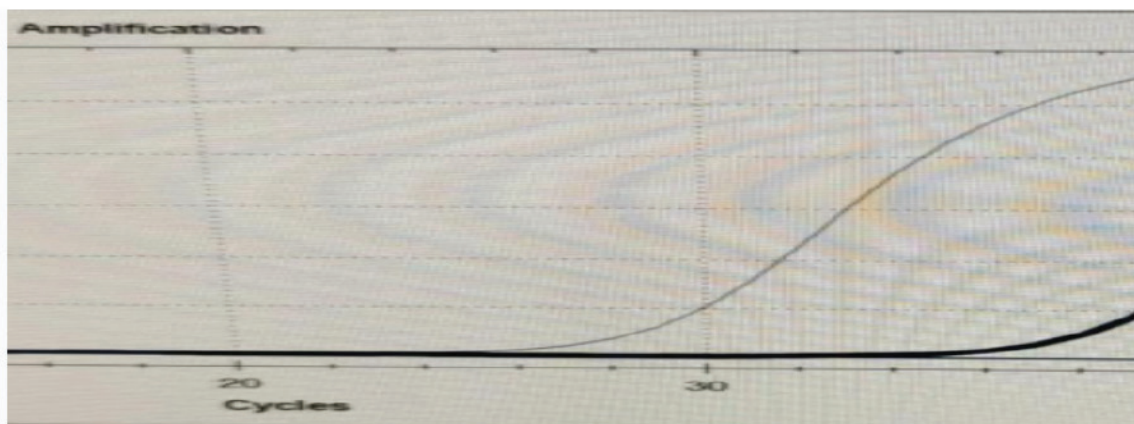
The COVID PCR test, which was studied from the concurrent nasopharyngeal sample, was also positive, patient given first dose of favipiravir.

The patient, who had GCS E2M4V1 in the follow-ups and could not protect the airway, was intubated and connected to a mechanical ventilator. The patient was transferred to the anesthesiology and reanimation ICU. Acyclovir treatment for HSV-1 encephalitis was continued in the patient who was transferred to the ICU, and molnupiravir treatment was started for COVID PCR positivity. It was also added to the 3<sup>rd</sup> generation cephalosporin treatment.

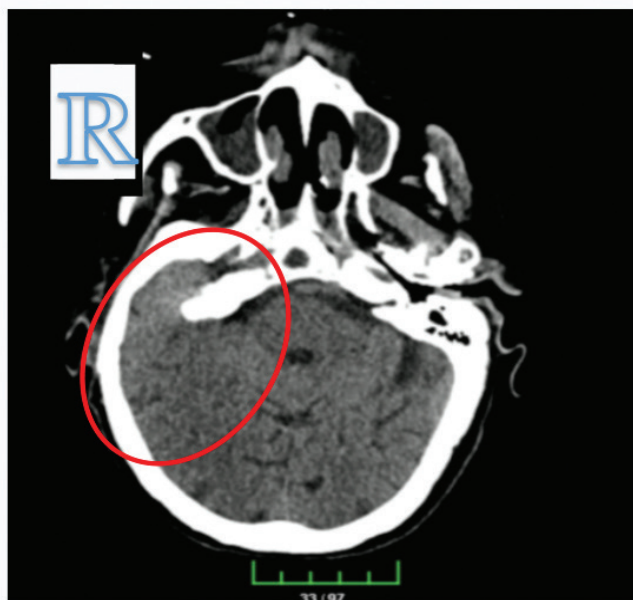The patient, who was extubated on the 7<sup>th</sup> day of the intensive care follow-up and weaned off the mechanical ventilator, underwent a lumbar puncture again on the 10<sup>th</sup> day of the intensive care hospitalization, and the viral panel studied from CSF was negative. COVID PCR, which was studied from CSF, was positive (Figure 1).

On the 11<sup>th</sup> day of her hospitalization in the ICU, the patient was intubated and connected to a mechanical ventilator due to the development of sudden breathing and cardiac arrest while the patient was being followed up in the nasal cannula. When the patient's hemodynamics was stable, brain CT was performed with the suspicion of cerebellar herniation.

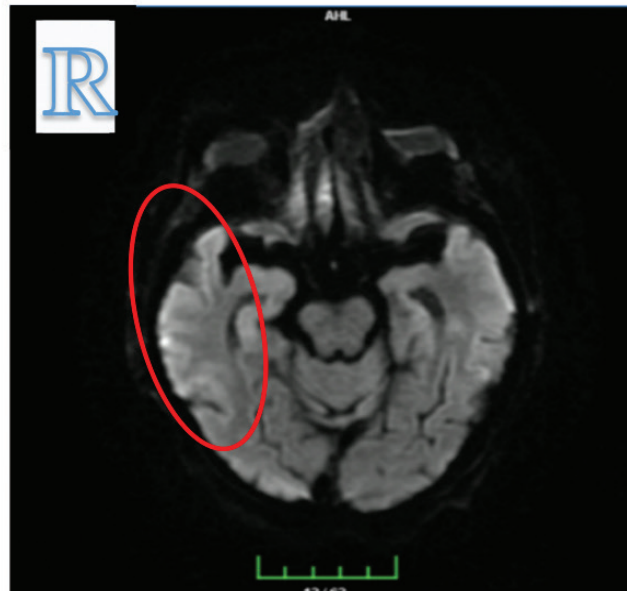
A suspicious involvement area was observed in the right temporoparietal region in the CT scan (Figure 2). Antiepileptic treatment was started for the patient who had refractory seizures in the follow-up; slow wave activity and occasional sharp wave activity were observed in the left anterior frontotemporal region in bedside electroencephalography. It was found to be significant in terms of left frontotemporal



**Figure 1.** COVID PCR diagram from CSF  
 COVID PCR: Coronavirus disease polymerase chain reaction, CSF: cerebrospinal fluid



**Figure 2.** Suspected temporoparietal involvement area in brain CT  
 CT: Computed tomography



**Figure 3.** Right temporal edematous appearance

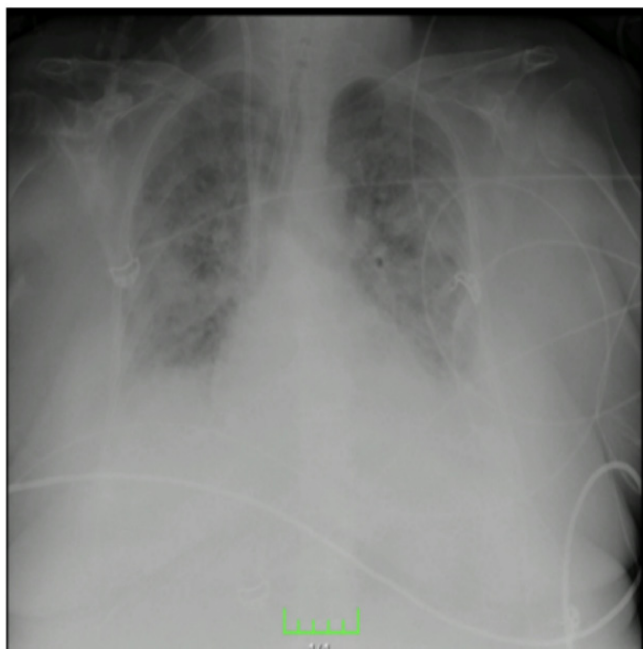
epileptic activity and focal organization disorder. Diffusion MRI taken on the 23<sup>rd</sup> day of ICU hospitalization showed an edematous appearance in the right temporal region, consistent with HSV encephalitis (Figure 3).

In the febrile period and in the tracheal aspirate culture taken at regular intervals, *Klebsiella pneumonia* and *Pseudomonas aeruginosa*; antibiotherapy was strengthened in the patient who had *Candida glabrata* growth in blood cultures. COVID PCR tests on the samples taken from the patient with deep tracheal aspirate were positive.

Prone position was tried in the patient with acute respiratory distress syndrome appearance on lung X-ray (Figure 4) and desaturated despite high mechanical ventilator pressure supports.

The patient, whose secondary bacterial infections were added to COVID pneumonia, died on the 40<sup>th</sup> day of intensive flow follow-up.

The consent of the patient’s family has been obtained for the presentation of the case.



**Figure 4.** ARDS view  
ARDS: Acute respiratory distress syndrome

## Discussion

In the literature, temporary immunosuppression has been identified in patients due to systemic inflammatory response caused by COVID infection, lymphopenia or steroid or IL-6 receptor antagonists used in the treatment (6). Studies reporting the respiratory system and systemic reactivation of HSV due to immunosuppression are available in the literature and a case has also been reported in the literature

(7,8). Due to the symptoms of encephalitis did not improve despite seronegativity of CSF for HSV under appropriate HSV treatment we concluded that covid and HSV are both the causes of encephalitis initially.

While there may be HSV reactivation due to immune dysregulation in COVID patients, it is necessary to consider isolated COVID central involvement.

Since its clinical diagnosis is easier with both imaging methods and laboratory examinations, and the treatment options are more known, HSV encephalitis is a more common and treatable encephalitis agent than COVID encephalitis.

With no consensus on its treatment, COVID encephalitis has a more widespread involvement and its pathogenesis has not yet been fully enlightened.

More studies are needed to enlighten COVID encephalitis.

### Ethics

**Informed Consent:** The consent of the patient's family has been obtained for the presentation of the case.

**Peer-review:** Externally peer-reviewed.

### Authorship Contributions

Surgical and Medical Practices: R.A., Concept: R.A., E.K., Design: R.A., Data Collection and/or Processing: R.A., Analysis and/or Interpretation: R.A., E.K., B.Y., Literature Search: R.A., E.K., Writing: R.A., E.K.

**Conflict of Interest:** No conflict of interest was declared by the authors.

**Financial Disclosure:** The authors declared that this study received no financial support.

## References

1. WHO COVID-19 Dashboard. Available from: URL: <https://covid19.who.int/>. Accessed July 5, 2023.
2. Islam MA, Cavestro C, Alam SS, Kundu S, Kamal MA, Reza F. Encephalitis in Patients with COVID-19: A Systematic Evidence-Based Analysis. *Cells* 2022;11:2575.
3. Gupta S, Dutta A, Chakraborty U, Kumar R, Das D, Ray BK. Post-COVID-19 HSV encephalitis: a review. *QJM* 2022;115:222-7.
4. Li YC, Bai WZ, Hashikawa T. The neuroinvasive potential of SARS-CoV2 may play a role in the respiratory failure of COVID-19 patients. *J Med Virol* 2020;92:552-5.
5. Moriguchi T, Harii N, Goto J, Harada D, Sugawara H, Takamino J, et al. A first case of meningitis/encephalitis associated with SARS-Coronavirus-2. *Int J Infect Dis* 2020;94:55-8.
6. Giacobbe DR, Di Bella S, Lovecchio A, Ball L, De Maria A, Vena A, et al. Herpes Simplex Virus 1 (HSV-1) Reactivation in Critically Ill COVID-19 Patients: A Brief Narrative Review. *Infect Dis Ther* 2022;11:1779-91.
7. Giacobbe DR, Di Bella S, Dettori S, Brucci G, Zerbato V, Pol R, et al. Reactivation of Herpes Simplex Virus Type 1 (HSV-1) Detected on Bronchoalveolar Lavage Fluid (BALF) Samples in Critically Ill COVID-19 Patients Undergoing Invasive Mechanical Ventilation: Preliminary Results from Two Italian Centers. *Microorganisms* 2022;10:362.
8. Ramírez-Colombres M, Maenza CE, Rocchetti NS, Gattino SP, Diodati S, Luchitta CA, et al. COVID-19 and herpesvirus encephalitis. *Rev Neurol* 2022;74:280-3.